


IAP GOA STATE CHAPTER

E-Bulletin



BULLETIN MARCH 2025

Activities from

JANUARY - MARCH 2025
ISSUE 12

GOA STATE CHAPTER

For Private Circulation

Table of Contents

Sr. No.	Title	Page No.
1	PRESIDENT’S ADDRESS – Dr. Swapnil Usgoankar	3
2	EDITOR’S NOTE	4
3	NON-COMMUNICABLE DISEASES	5
4	AUTISM AWARENESS	8
5	ADRENAL INSUFFICIENCY WITH XYDSO : A RARE PRESENTATION OF MIRAGE SYNDROME IN A NEONATE	13
6	RARE CASE-PRESENTATION OF JUVENILE POLYARTERITIS NODOSA WITH GIANT CORONARY ARTERY ANEURYSM AND MULTIPLE SPLENIC INFARCTS - A CASE REPORT	15
7	PROGRESSIVE FAMILIAL INTRA HEPATIC CHOLESTASIS TYPE 4: A CASE REPORT	20
8	CYTO - MEGALOVIRUS COLITIS IN AN IMMUNOCOMPETENT PATIENT	24
9	POEM ... WHO IS SHE?	27
10	ACTIVITIES AND ACHIEVEMENTS	29

PRESIDENT'S ADDRESS

Greetings from IAP Goa State chapter

Dear members and friends

“Writing is the painting of the voice” -said Voltaire, the great French writer and philosopher.

My dear friends we as individuals have our talents, experiences, ideas, knowledge and views. However we somehow never got an opportunity or forum to express and publish it due to various reasons. By way of this newsletter of IAP Goa State chapter we offer you a medium to express yourself and showcase the immense talent that you all possess to the world.

I am really fortunate to have our able, enthusiastic and dynamic duo of editors Dr.Kritika Kamat Wagle and Dr.Siddhi Akarker serving as rudders in this endeavour of mine. I wish them best wishes, support and blessings for an exciting term.

I welcome you to this beautiful, informative and exciting journey of profound knowledge, sharing of views, experiences and achievements which will leave our small yet closely knitted family of Goa IAP healthy and lively.

Because as the famous 17 th century English essayist Joseph Addison once famously said *“Reading is to the mind what exercise is to the body”*

Happy Reading.

Yours Sincerely,

Dr.Swapnil Keshav Usgaonkar

The President,

IAP Goa State Chapter

2025-2026

EDITOR'S NOTE

Greetings to all fellow IAPians!!!

It gives us immense pleasure to present to you the 12th issue of the IAP GOA State Chapter e-bulletin.

We express our sincere gratitude to all the IAP GOA members who have contributed to our e-bulletin through articles, case discussions, activities and achievements and much more.

A big thank you to our seniors for their guidance and assistance to help us restart the bulletin after a sabbatical of nearly five years.

Hoping that the enthusiasm to contribute to this platform gets better with each passing term.

Thanking you,

Dr. Kritika Wagle & Dr. Siddhi Akarker

NON COMMUNICABLE DISEASES IN ADOLESCENCE

Non-communicable diseases (NCDs) are silent killers and are on the rise globally. The main NCDs include cardiovascular diseases, cancer, chronic respiratory diseases, diabetes mellitus, and hypertension. NCDs account for 70% of all deaths worldwide including many premature deaths between the ages of 30 to 70 years.

Adolescence is a critical period in life, during which lifestyle choices significantly impact future health and well-being. Adolescents may adopt risky health behaviors and habits that contribute to the development of NCDs- such as consumption of JUNKS (junk food, unhealthy beverages), smoking, alcohol use, and physical inactivity. Additionally, mental health disorders can negatively affect their quality of life.

Disability-adjusted life years (DALYs) due to NCDs have increased from approximately 35% to 45% in both boys and girls. According to the Comprehensive National Nutrition Survey (CNNS) 2016-2018, nearly 50% of adolescents in India are at increased risk of developing diabetes cardiovascular diseases, and high blood pressure.

The Centers for Disease Control and Prevention (CDC) recommends preventing NCD risk factors such as physical inactivity, unhealthy diet, tobacco use, and alcohol consumption.

As per UNICEF, efforts should focus on addressing cardiovascular diseases, diabetes, cancer, chronic respiratory diseases, mental health disorders, and injuries. NCDs are a growing threat to children and adolescents, undermining their rights to health, nutrition, education, and play. Globally, more than 2.1 billion children and adolescents under the age of 20 are affected by NCDs.

Diet, stress, substance use, and environmental toxins can trigger epigenetic changes, increasing adolescents' vulnerability to various NCDs.

Risk Factors :

- 1) Modifiable: Unhealthy diet, physical inactivity, tobacco use, alcohol consumption.
- 2) Non-modifiable: Family history of hypertension, diabetes, or cardiovascular diseases.

Additional contributors include air pollution, urbanization, exposure to environmental toxins, and lower socioeconomic status, which limits access to nutritious food and quality healthcare. Peer pressure can lead adolescents toward substance use, smoking, alcohol consumption, and unhealthy eating patterns.

Early Screening of NCDs in Adolescents

Early screening is crucial for timely intervention and prevention.

Pediatricians should recognize risk factors early and provide anticipatory guidance.

Screening should include assessment of:

- a) Family history of NCDs
- b) Dietary habits
- c) Physical activity levels
- d) Screen time
- e) Substance use
- f) Physical signs of NCDs
- g) Sexual Maturity Rating (SMR)

Interventions should address:

- 1) Physical activity
- 2) Healthy eating habits
- 3) Screen time reduction
- 4) Mental health concerns

Management Guidelines:

1. Encourage the entire family to adopt and maintain healthy habits.
2. Parents should serve as positive role models by living a healthy lifestyle.
3. The family should engage in physical activity and consume a balanced diet together.
4. Recommended daily intake:
 - 4-5 servings of fruits and vegetables
 - half a plate of vegetables/greens
 - one-fourth plate of high-fiber cereals
 - one-fourth plate of protein (fish, chicken, eggs, dals, sprouts)
 - Avoid carbonated/caffeinated drinks, sugar-sweetened beverages, processed foods, excessive salt, sugar, trans- fats and saturated fats.
5. Engage in atleast 60 minutes of moderate to vigorous physical activity on at least 5 days per week.
6. Limit sedentary activities (TV, mobile use, video games) to less than 2 hours daily.
7. Screen for and address mental health issues.
8. Support government regulations that restrict marketing of junk-food and sugar-sweetened beverages to children and adolescents.
9. Promote the adoption of IAP's SSS (Sankalp Swasthya Sampurna) Program in schools to increase awareness about healthy lifestyles among adolescents.

Dr. Sushma P. Kirtani
Adolescent Pediatrician
EB 24/25 GOA

AUTISM AWARENESS

**DR. ELYSKA DE SA, NODAL OFFICER,
DEIC, SOUTH GOA DISTRICT HOSPITAL, MARGAO**

Autism or Autism spectrum disorder (ASD) is a neurodevelopmental condition. In simple words, it is a condition that affects the signaling /synapses in the brain resulting in developmental issues in the child in the communication and socialization domain.

As the name represents, it is a spectrum wherein every person or child with autism is unique and may have a broad variety of symptom presentations.



Myths

- Often gets misdiagnosed as a case of speech delay
- It is a result of poor upbringing or neglect of the parents
- ‘Just an excessively naughty child’.
- Will get better with time
- Speaking late runs in the family
- Autism is caused by vaccines
- All autistic individuals have intellectual disability

Autism is far more common than we can imagine. It is said that the prevalence of this condition is 1:64 (Uke et al. 20 June 2024; pubmed). In India an estimate of 1.8-2 million children are said to be having this condition. Currently in district early intervention centres (DEIC) in Goa we see at least 2-4 new ASD cases per week; more in males than females. No systemic epidemiological review of Indian data available as of now to estimate prevalence in this country.

Facts

- It is present since birth and is not a condition that develops later in life
- The earliest signs and symptoms can be picked up at around 9 months to 1 year of age
- Autistic kids may 'look' absolutely fine just like their neurotypical peers.
- There are no physical abnormalities in most cases.
- Not all autistic kids are hyperactive. Some may be hypoaroused and withdrawn
- Autistic kids have feelings too, just a difficulty in expressing them.
- Some autistic individuals may be highly independent preferring to do things themselves
- An autistic person will remain autistic for life. However symptoms may change over time, masking of symptoms may set in as the person gets older.
- Autistic kids can be gifted too (autistic savants). Photogenic memory, hyperlexia (reading beyond age), hypercalculia (doing mental maths beyond age)are some gifts

SIGNS AND SYMPTOMS

DIFFICULTIES IN SOCIALIZATION/ COMMUNICATION	RESTRICTIVE /REPETITIVE BEHAVIORS
<ul style="list-style-type: none"> ➤ Doesn't respond to their name when called ➤ In their own world, sometimes continuously ➤ talking to self ➤ Doesn't make eye contact when spoken to ➤ Indicates needs by pulling parent/ caregiver ➤ (hand borrowing) to object of need ➤ No back and forth conversation or lacks ➤ INTENT to communicate ➤ Not involving others in play ➤ No meaningful COMMUNICATIVE speech by 2.5-3 years of age 	<ul style="list-style-type: none"> ➤ Repeating whatever is asked ➤ (Echolalia)without any meaning ➤ Repetitive motor movements like Spinning around continuously/pacing up and down/jumping/running continuously ➤ Meaningless repetitive play with the same toys over and over again ➤ Insistence on sameness and following same routines, emotional outbursts when not allowed to ➤ Strong attachment to inanimate objects like toys/ household items ➤ Overtly/ under sensitive to certain smells/textures and taste

A diagnosis of autism needs a thorough evaluation by your pediatrician and cannot be made in an OPD visit of 5 mins.

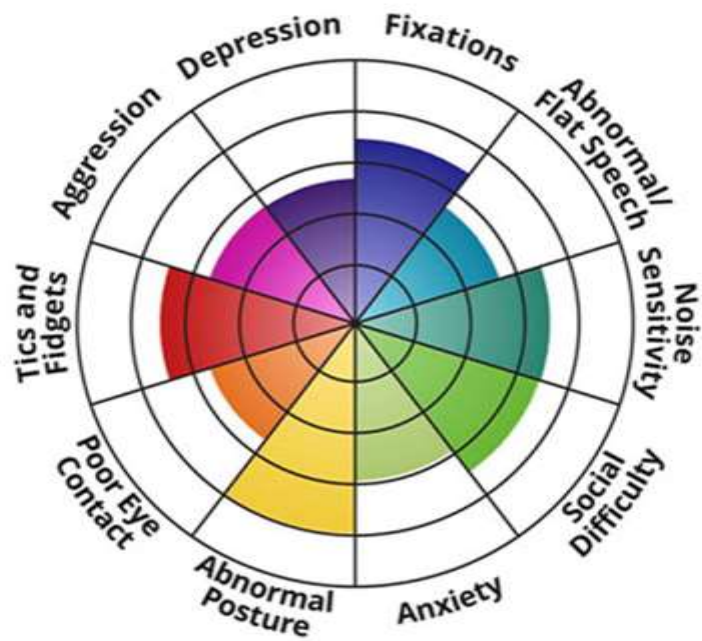
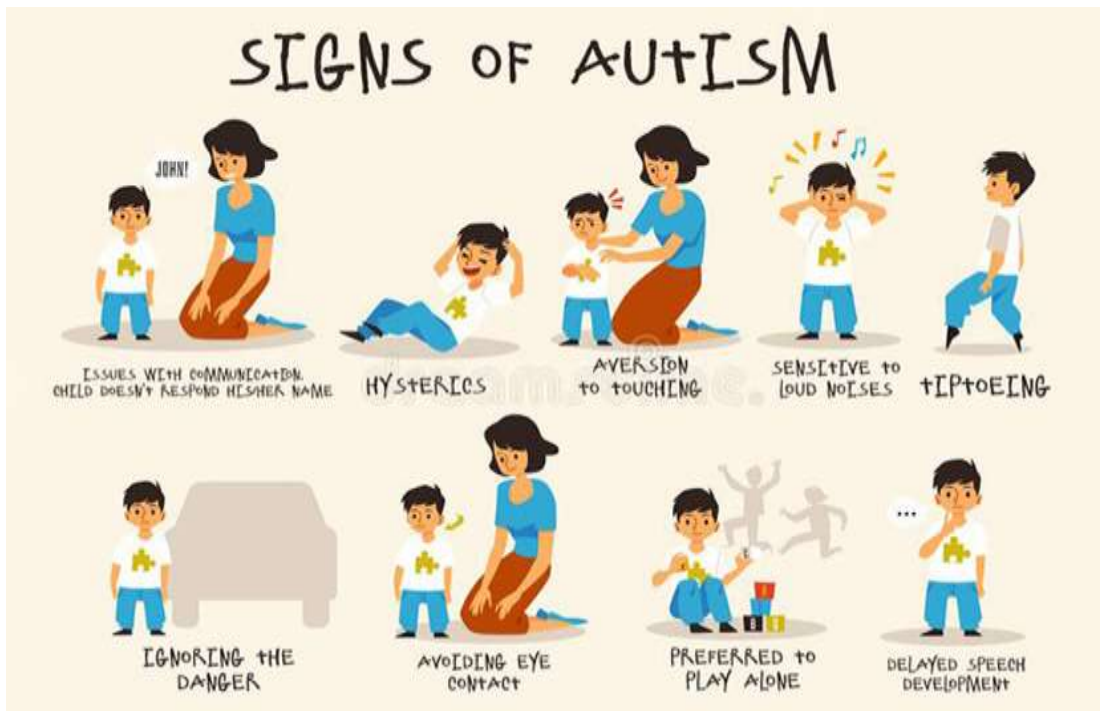All these symptoms can ultimately lead to a delay in expressive language by 3-4 years of age which is the reason why most caregivers/parents approach professionals. This may further lead to academic issues and difficulty in adjusting in school, untoward behaviours in school, difficulty in making friends or in cooperating in play with other kids.

It is important to know that the autism spectrum is not linear. It looks more like a wheel. Autistic attributes may be present in different intensities in an autistic individual also not all attributes are present in all individuals. Each autistic person is different.

POINTS TO REMEMBER

- Early identification and intervention is the key! Maximum brain development occurs in the first 5 years, of which 90% is in the first 2 years of life. Hence seeking help at this stage is important and will result in best outcomes.
- Training of family members (parents/ caregivers/grandparents) is of utmost importance
- Human engagement in the early years is medicine for the child (be it with family/therapists/doctors/teachers anyone).
- There are no drugs to CURE autism or to make a person non autistic.
- Management of this condition may need a multi-disciplinary team involving various therapies, environmental changes, lifestyle modifications etc.

Autistic children have many strengths which can surface over time. Patience from the family is crucial for optimal outcome.



TIPS FOR PARENTS

- **ENJOY YOUR CHILDREN..**Engage with them meaningfully at every opportunity you get
- Be fully present and **CONNECTED** with your child even in the smallest day to day routines like feeding/ bathing/ dressing.
- Avoid screens up to 18 months to 2 years of age (except meaningful video calls to family who is away). **DO NOT USE SCREENS AS BABY SITTERS..**
- Have a more or less fixed routine for the child/ rules for the house
Setting limits for behaviours should start at an early age.
- Be patient and consistent with your efforts. Achieving milestones and building skills (which happens with appropriate therapy and intervention) don't happen overnight and may take months to years.
- Understand your child's strengths and weaknesses and celebrate small achievements.
- Keep your expectations as per their mental age and not actual age.
- Do not neglect self care or isolate yourself from society, be in touch with other parents

Adrenal Insufficiency with XYDSD: A Rare Presentation of MIRAGE Syndrome in a Neonate

AUTHORS- Dr. Radhika D R, Dr. Rajat Assoldekar, Dr. Kavita Sreekumar,
Dr, Annely D'Lima, Dr. Vaishali Joshi

Introduction:

MIRAGE syndrome is rare autosomal dominant disorder characterized by Myelodysplasia, Infection, Restricted growth, Adrenal hypoplasia, abnormal Genital phenotype and Enteropathy 1,2 .

It is caused by mutations in the SAMD9 gene 2,5 . We report a case of neonate with adrenal insufficiency, phenotypically female at birth, but later confirmed to have male karyotype.

Case Description:

A female baby was born out of nonconsanguineous marriage at 31.4 weeks of gestation with asymmetric IUGR with extensive hyperpigmentation at birth,. Suspected as a case of carbon baby syndrome or dermal melanosis(fig-1).

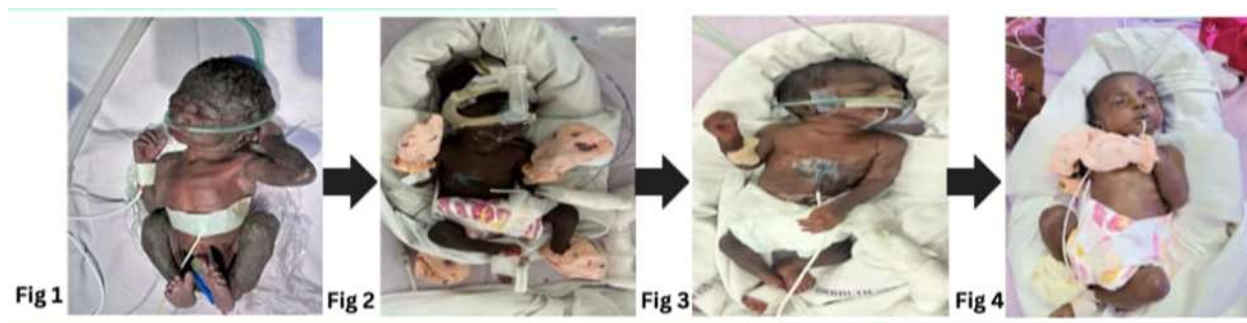
On Day 4 of life there was deepening of hyperpigmentation with acute clinical worsening and investigations were suggestive of acute adrenal crisis 3,4 i.e. hyperkalemia and hyponatremia, metabolic acidosis, polyuria and severe dehydration(fig-2).

Further workup was suggestive of very high ACTH with low 17-OH progesterone and testosterone suggestive of proximal steroid biosynthesis pathway defect. Baby also had anemia, thrombocytopenia and feed intolerance with difficulty in establishment of full feeds. Baby was started on hydrocortisone and fludrocortisone with clinical improvement esp. hyperpigmentation(fig-3).

Further evaluation revealed 46XY karyotype, absence of gonadal tissues and whole exome sequencing confirmed heterozygous missense variant c.2054G>A in exon 3 of SAMD 9 gene suggestive of MIRAGE syndrome. The child was discharged on oral hydrocortisone and fludrocortisone with normalized electrolyte status and healthy weight gain(fig-4).To the best of our knowledge such case has been reported approximately less than 50 instances worldwide and first of such case reported in India.

Conclusion:

Early diagnosis and evaluation for adrenal insufficiency along with genetic analysis is essential for diagnosing rare genetic disorders like MIRAGE syndrome, allowing for timely management and appropriate genetic counseling.



References:

1. Narumi S. Discovery of MIRAGE syndrome. *Pediatrics International*. 2022 Jan;64(1):e15283.
2. Onuma S, Wada T, Araki R, Wada K, Tanase-Nakao K, Narumi S, Fukui M, Shoji Y, Etani Y, Ida S, Kawai M. MIRAGE syndrome caused by a novel missense variant (p. Ala1479Ser) in the SAMD9 gene. *Human genome variation*. 2020 Mar 5;7(1):4.
3. Yiğit Ş, Turkmen M, Tuncer O, Taskin E, Güran T, ABACI A, Catli G, Tarım ÖM. Neonatal adrenal insufficiency: Turkish neonatal and pediatric endocrinology and diabetes societies consensus report. *TURK PEDIATRİ ARSIVI-TURKISH ARCHIVES OF PEDIATRICS*. 2018;53.
4. Duro IP, Mosca S, Araújo G, Lorenzo J, Figueiredo C, Freitas J, Oliveira MJ, Borges T. Neonatal adrenal insufficiency—beyond the common causes. *Journal of Pediatric and Neonatal Individualized Medicine (JPNIM)*. 2022;11(1):e110108-.
5. Chin X, Sreedharan AV, Tan EC, Wei H, Kuan JL, Ho CW, Lam JC, Ting TW, Vasanwala RF. MIRAGE syndrome caused by a de novo c. 3406G> C (p. Glu1136Gln) mutation in the SAMD9 gene presenting with neonatal adrenal insufficiency and recurrent intussusception: A case report. *Frontiers in Endocrinology*. 2021 Sep 29;12:742495.

Rare case-presentation of Juvenile Polyarteritis Nodosa with Giant Coronary Artery Aneurysm and Multiple Splenic Infarcts - A Case Report

AUTHORS: Dr. Rajat Sinai Assoldekar, Dr. Shilpa Joglekar, Dr. M Prabha Prabhu, Dr. Vaishali Joshi

ABSTRACT

Background

Juvenile Polyarteritis Nodosa (PAN) is a rare necrotizing vasculitis mainly affecting the medium-sized muscular arteries. The involvement of the cardiovascular system is uncommon in this disease. Also, the occurrence of coronary artery aneurysms and splenic infarcts is extremely rare.

Case Presentation

In this case report we describe a 10-year-old boy who presented with low-grade fever, significant weight loss and abdominal pain for 1 month. Child was initially treated as a case of PUO with no clinical response to treatment. The USG abdomen revealed splenic echogenicities, CECT abdomen was suggestive of splenic infarct. 2D ECHO followed by Cardiac CT revealed giant coronary artery aneurysms. Child was diagnosed as a case of Polyarteritis Nodosa (Radiologically) and was started on Cyclophosphamide and Prednisolone and prophylactically on Aspirin and walfarin. Child showed good clinical improvement to the treatment. This case illustrates a rare presentation of giant coronary aneurysms with splenic infarcts in a setting of juvenile PAN.

Keywords: Polyarteritis Nodosa, Coronary Artery Aneurysms, Splenic Infarcts

BACKGROUND

Juvenile PAN is a rare necrotizing vasculitis mainly affecting the medium-sized muscular arteries.

The classification criteria from EULAR/PRES are as follows:

A. Histopathology of necrotizing vasculitis/angiography abnormalities PLUS

B. One of the five

Skin involvement

Myalgias

Hypertension

Peripheral neuropathy

Renal involvement

The involvement of the cardiovascular system is uncommon in this disease. The occurrence of coronary artery aneurysms and splenic infarcts is extremely rare.

CASE PRESENTATION

Case of 10-year-old boy who presented with fever for 1 month of high-grade spikes, significant weight loss and decreased appetite. Child had intermittent arthralgias and abdominal pains (moderate grade). Child was admitted as a case of PUO to rule out Kochs / inflammatory disorders.

No h/o night sweats

No h/o noticing neck masses or swellings elsewhere in the body

No h/o noticing marked pallor/petechiae

No h/o skin rash

Blood investigations were suggestive of Microcytic Hypochromic Anaemia with Mild aniso-poikilocytosis with thrombocytosis. RFT/LFTs were normal. Serum Procalcitonin was negative. ESR was 72 mm/ hr. SMP and serology for Dengue were negative. Urine routine/microscopy/culture were negative. Sputum CBNAAT were negative. Blood Widal was negative. Serum Iron was reduced (20 mcg/ml), Serum ferritin was elevated (514 ng/ml) with normal TIBC.

ANA/Anti DsDNA was negative. RA factor was negative. P ANCA / C ANCA was Negative. Hep B/Hep C/HIV Negative.

Child was started on Inj. Amoxicillin Clavulanic acid and was later upgraded to Inj. Cefotaxime with Inj. Clindamycin after 4 days. Blood BACTEC was sterile hence IV antibiotics were stopped after 7 days. Trial of Doxycycline was given for 5 days.

Child had persistent moderate to high grade spikes with moderately severe abdominal pain. USG Abdomen (D10 of Admission) showed mild hepatomegaly with few well-defined areas of altered echotexture at inferior splenic pole.

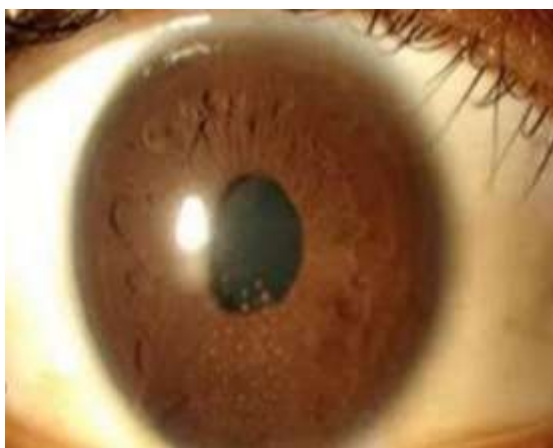
CECT Abdomen showed - Mild Hepatomegaly and Renomegaly. Microaneurysms in arcuate and interlobar branches of bilateral renal arteries with luminal irregularities and string of beads appearance. Microaneurysms in hepatic parenchyma. Microaneurysms in splenic parenchyma with wedge shaped geographic hypodensities in peripheral parenchyma s/o infarction. Few left para-aortic and mesenteric lymph node enlargement.

Rheumatology opinion taken and was started on Oral Prednisolone @ 1mg/kg with gradual tapering over 4 months. Cyclophosphamide @ 600mg/m² BSA for 4-6 months till remission achieved. Oral Aspirin 75 mg/day and Oral Warfarin (Target INR of 2-2.5) was added. 2D ECHO and Cardiac CT was suggestive of all coronary's aneurysms. Mild LV dysfunction with EF 50%.

Fig. 1. CECT Abdomen showing string of bead appearance

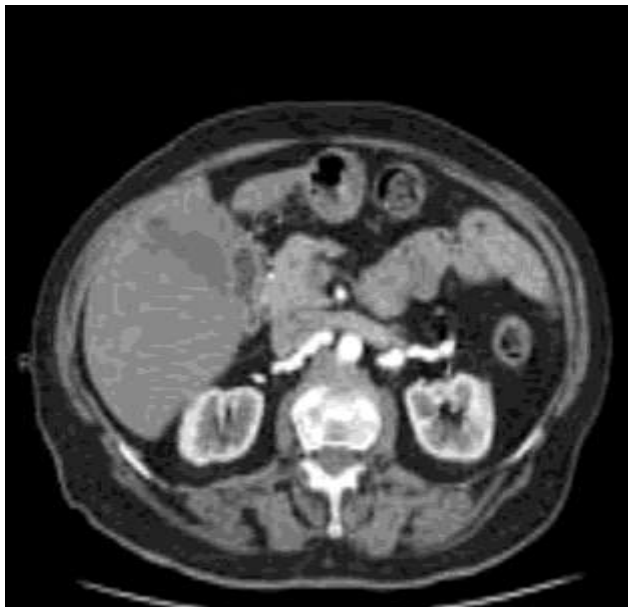

Fig.2.Ophthalmology evaluation suggestive of Chronic Granulomatous Uveitis .



DISCUSSION

PAN was first described by Kussmaul and Maier in 1866. It is a predominantly medium vessel necrotizing vasculitis. Aneurysms and stenosis form at irregular intervals throughout the affected vessels. Though PAN affects several medium vessels, the involvement of coronaries is rare and splenic vessel involvement is hardly seen.

In our case, it affected the child in early adolescence and presented only with constitutional symptoms the predominant being Pyrexia of Unknown Origin. Case was extensively worked up for etiology until finally CT Abdomen clinched the diagnosis. 2D ECHO was suggestive of coronary ectasias, ECG was normal. Child was started on steroids as mainstay and cyclophosphamide therapy. During the course of treatment child was hypertensive hence was started on antihypertensive drugs.

Children with PAN may have a wide variety of cardiac manifestations. In a case series of 31 children with PAN, 5 demonstrated cardiac involvement in the form of pericarditis, arrhythmias, cardiac failure.

These patients were treated with steroids and immunomodulators. PAN is often confused with Kawasaki disease and is often misdiagnosed. The mainstay of treatment in juvenile PAN mainly revolves around steroids with cyclophosphamide therapy followed by immunomodulators like azathioprine as steroid sparing agent. In presence of coronary aneurysm/ectasias, prophylactic aspirin with warfarin is also required to prevent future myocardial infarction.

CONCLUSION

We report a rare case of Juvenile PAN and multiple giant coronary artery aneurysms with splenic infarcts. Medical management with IV cyclophosphamide and high-dose steroids led to resolution of active vasculitis.

CONSENT

Written informed consent was obtained from patient's parents for publication of this case & accompanying images.

AUTHOR DETAILS

Dr Rajat Sinai Assoldekar is Third Year post graduate student in Department of Pediatrics, Goa Medical College

Dr M Prabha Prabhu is Second Year post graduate student in Department of Pediatrics, Goa Medical College

Dr Shilpa Joglekar is an Associate Professor in Department of Pediatrics, Goa Medical College

Dr Vaishali Joshi is Professor and Head of Department, Department of Pediatrics, Goa Medical College

CONFLICT OF INTERESTS

All authors do not report any conflict of interest in this work.

REFERENCES

1. Therese LC, Dawn MW, Kanwal MF, Robert HP, Norman TI. Giant coronary artery aneurysms in juvenile polyarteritis nodosa: a case report. *Pediatric Rheumatology* 2012,10.1
2. Ozen S, Fuhllbrigge RC: Update in pediatric vasculitis. *Best Pract Res ClinRheumatol* 2009, 23.679-688
3. Ozen S, Pistorio A, Lusan SM, Bakkaloglu A, Herlin T, Brik R, Buoncompagni A, Lazar C, Bilge I, Uziel Y, et. Al EULAR/PRINTO/PRES criteria for Henoch-Schonleinpurpura, childhood polyarteritis nodosa, childhood Wegner's granulomatosis and childhood Takayasu arteritis: Ankara 2008. Part2: Final classification criteria. *Ann Rheum Dis* 69.798-806
4. Maillard-Lefebvre H, Launay D, Mouquet F, Gaxotte V, Hachulla E, de Groote P, Lambert M, Queyrel V, Morell- Dubois S, Beregi JP, et. Al polyarteritis nodosa-related coronary aneurysms. *J Rheumatol* 2008, 35.933-934
5. Takahashi M, Inflammatory diseases of the coronary artery in children. *Coron Artery Dis* 1993, 4. 133-138
6. Gedalia A, Cuchacovich R: Systemic vasculitis in childhood. *CurrRheumatolResp* 2009, 11.402-409
7. Sugahara Y, Ishii M, Muta H, Semura M, Iemura M, Matsuishi T, Kato H: Warfarin therapy for giant coronary aneurysm prevents myocardial infarction in Kawasaki disease. *PediatrCardiol* 2008, 29.398-401

Progressive Familial Intrahepatic Cholestasis Type 4: A Case Report

Authors: Sailee Raiker, Anagha Dubhashi, Vaishali Joshi, Department of Pediatrics, Goa Medical College

INTRODUCTION

Progressive familial intrahepatic cholestasis (PFIC) is a group of rare autosomal recessive genetic disorders involving defects in bile acid secretion or transport. There is a wide spectrum of manifestations ranging from neonatal cholestasis, recurrent cholestasis, refractory pruritus, growth failure, childhood liver failure, portal hypertension to advanced end-stage liver disease.

Classically, PFIC is classified into three subtypes: PFIC1, PFIC2, and PFIC3 according to the timing of their discovery. With the advancements in genetic analyses, newer subtypes are being discovered. PFIC4 was first reported in 1991 by Gumbiner *et al.* In PFIC4, there is deficiency in a protein called tight junction protein 2 (TJP2) or zona occludens 2 due to mutation in the tight junction protein 2 (TJP2) gene.

This results in reduced integrity of the canalicular membrane and reflux of bile acids into hepatocytes, with their deleterious effect in potentiating hepatocyte damage and cholestasis. TJP2 has a widespread expression, including the respiratory and central nervous systems. Here we are presenting a case of a 6 month old female infant brought with jaundice and deranged liver parameters found to have PFIC type 4 upon appropriate clinical and investigative evaluation.

CASE REPORT

A 6-month-old boy born out of non consanguineous marriage presented to our institute with a 3-month history of progressive generalized jaundice and persistent pruritus. No family history of cholestasis or hepatic disease was reported. Antenatal History: No h/o fever with rash, lymphadenopathy during pregnancy. No h/o pruritis, fatty liver of pregnancy.

Natal History: Term / Birth weight- 2.640 kg/ Appropriate for Gestational age/ born via Emergency LSCS (Ind: non- progression of labour) / Baby cried immediately after birth, breastfed within 1 hour of birth, no h/o NICU admission. Urine and meconium passed within 24 hours of birth. No h/o phototherapy or exchange transfusion.

On clinical examination, the patient was markedly icteric and pale. His growth parameters were affected; weight and length were below the 25th percentile for age despite being within the normal range at birth. He had marked hepatomegaly, splenomegaly and mild ascites. He had scratch marks all over his body, especially around his face. His urine was dark. At this stage, biliary atresia and other causes of obstructive jaundice in this age group such as PFIC, Alagille syndrome and inspissated bile syndrome were considered.

Investigations: LFT- Total serum bilirubin- 18.9 mg/dl (elevated), Direct bilirubin- 10.7 mg/dl SGOT- 970 IU/ L (elevated), SGPT- 440 IU/L (elevated), ALP - 865 IU/L (elevated), GGT- 65 IU/L, PT-INR - normal , Sr Albumin – 3.0 gm/dl. CBC- Hb- 10.8 g%, Retic count - 2.4 %, Peripheral smear - Dimorphic anemia, no hemolysis, Direct Coombs test- negative, Thyroid Function test- normal , USG abdomen – hepatosplenomegaly with minimal ascites, no evidence of triangular cord sign, Serum bile acid - 221.3 umol/ L (elevated).

Ammonia	84 (29-70mcg/dl)
Urine reducing substances	negative
Tandem Mass spectrometry	NAD
Fundus	normal
Ferritin	91 (50-200 ng/ml)
Urine CMV PCR	negative
DCT	negative
Hb electrophoresis	normal
Stool stercobilinogen	Weakly positive
2D Echo	normal
Cranial Ultrasound	normal
Viral markers	negative

HIDA Scan was normal. Pediatric surgery opinion was sought and patient was taken up for laparotomy. Intra hepatic cholangiogram done revealed free flow into the duodenum confirming patent CBD. Liver biopsy sample was taken which showed marked pseudoglandular transformation of almost all of the hepatocytes with canalicular cholestasis, florid ductular proliferation, and mild ductopenia. Thus, PFIC was the prime consideration.

The patient was on nutritional management with adequate calories and proteins in addition to MCT. She was initiated on high doses of vitamin D (2000 units/day) based on her serum vitamin D level. She also received the recommended daily doses of vitamins A and E. UDCA dose was escalated according to clinical and laboratory findings.

Whole-exome sequencing was done to detect the exact genetic mutation. A homozygous pathogenic variant in TJP2 was identified, which was consistent with the diagnosis of progressive familial intrahepatic cholestasis type 4 (OMIM: 615878). The patient continued on her nutritional and medical management however, the parents thereafter requested for a discharge discharge for referral to a higher centre.

DISCUSSION

PFIC type 4 represents a new entity of PFIC that evolved after the advances in genetic testing. The exact incidence of PFIC4 is not well known due to the limited number of studies, which are mostly case reports or small case series. PFIC1 and PFIC 2 usually occur in early infancy and are caused by a mutation in the ATP8B1 and ABCB11 genes, respectively. They are characterized by having a normal level of GGT, compared to PFIC3 that occurs in adolescents due to a mutation in the ABCB4 gene and has high GGT levels.

In PFIC4, there is a mutation in the TJP2 gene, which is a member of the membrane-associated guanylate kinase homolog family, located on the long arm of chromosome 9. It encodes a protein called tight junction protein 2 (TJP2). This encoded protein is an integral component of the tight junction barrier in epithelial and endothelial cells, which are crucial for proper assembly of tight junctions. Deficiency of TJP2 protein results in reduced integrity of the canalicular membrane and reflux of bile acids through the intercellular spaces into the hepatocytes, causing liver damage and progressive cholestasis. All homozygous mutations cause deficient TJP2 protein and complete loss of function. Missense and frame deletion lead to milder disease due to residual TJP2 protein expression.

Medical treatment for PFIC4 using UDCA (10–30 mg/kg/day), fat-soluble vitamins, MCT, and cholestyramine (240–400 mg/kg/day) can be effective in some cases. Surgery is indicated if there is intractable pruritus despite optimum treatment. Other indications include failure to thrive and nutritional deficiencies. Molecular genetic diagnosis is considered the test of choice in diagnosing PFIC type as it is non invasive unlike liver biopsy. This can be done using next-generation sequencing (NGS) . Whole-exome (WES) or whole-genome (WGS) sequencing can be done in cases with negative targeted gene analysis. Genetic counselling for parents is crucial as it is an autosomal recessive disorder.

REFERENCES

1. Abokandil, M.A., Waheeb, S., Zaghloul, W. *et al.* Progressive familial intrahepatic cholestasis type 4: a case report. *J Med Case Reports* **18**, 434 (2024).
<https://doi.org/10.1186/s13256-024-04662-5>
 2. Bull LN, Thompson RJ. Progressive familial intrahepatic cholestasis. *Clin Liver Dis.* 2018;22(4):657–69.
 3. Srivastava A. Progressive familial intrahepatic cholestasis. *J Clin Exp Hepatol.* 2014;4(1):25
 4. Baker A, Kerkar N, Todorova L, Kamath BM, Houwen RHJ. Systematic review of progressive familial intrahepatic cholestasis. *Clin Res Hepatol Gastroenterol.* 2019; 43(1):20–36.
-

CYTOMEGALOVIRUS COLITIS IN AN IMMUNOCOMPETENT PATIENT

Authors: Prabha M, Anagha Dubhashi, Vaishali Joshi, Department of Pediatrics, Goa Medical College

INTRODUCTION

Cytomegalovirus (CMV) is a ubiquitous double stranded DNA virus, and a cause of significant morbidity and mortality among congenitally infected children and immunocompromised hosts. Among apparently immunocompetent children, post natal CMV infection is generally considered to be asymptomatic in the neonate, and is occasionally associated with a mononucleosis-like syndrome of fever, malaise, and mild hepatitis in older individuals.

While in recent years, an increasing number of invasive CMV infections have been recognized among apparently immunocompetent adults, as well as in preterm infants presenting with necrotizing enterocolitis (NEC), CMV infection is rarely considered as a cause of infectious diarrhoea in otherwise healthy children.

Our patient was a 7 month girl presenting with pyrexia and bloody diarrhoea. Her evaluation revealed CMV infection which was treated well with Ganciclovir without any complications.

CASE REPORT

A 7 month old girl with fever of unknown origin and persistent diarrhoea since 2 months was admitted to the pediatric ward of Goa Medical College.

The stools were initially watery at onset and progressed to the passage of blood clots thereafter. She was the fourth child of the family born out of a non consanguineous marriage with an unremarkable birth history. She was exclusively breastfed for the first six months and recently started on rice based cereal. She had no history of loss of weight or abdominal distension.

There was h/o autoimmune thyroiditis in elder sibling and young stroke in paternal uncle. On admission, her weight and height were between 25-50 th percentile for her age.

The patient appeared well with no signs of dehydration. On examination there was no evidence of organomegaly, skin rash, oral thrush and the anus was normal with no fissure or ulcer. Initial differentials included infective diarrhoea, pseudomembranous colitis, inflammatory bowel disease and primary immunodeficiency disorder.

The laboratory investigations revealed anaemia (Hb 7.5 gm/dl), leukocytosis (WBC 20000, PMN 40%), platelet count of 165000, ESR, CRP, renal and liver function tests were normal. Coagulation workup was normal with a Prothrombin Time of 12 s with INR of 1, aPTT was 32s. Blood BACTEC, urine and stool cultures showed no growth on multiple occasions as well as stool Clostridium difficile PCR was negative.

Abdominal ultrasonography, CT Abdomen, Chest x ray were essentially normal. Stool Calprotectin was mildly elevated. Colonoscopy was performed up to sigmoid colon. No evidence of polyps, ulceration or inflammation was noted. However biopsy was not taken.

Vasculitis workup (p-ANCA, c-ANCA) was negative. Immunology evaluation consisting of HIV antibody, quantitative immunoglobulins and T-cell, B-cell and NK-cell subsets, was normal.

NBT was 100%. Whole exome sequencing report was awaited.

CMV Viral load was 625IU/ml with 418 copies/ml and Urine CMV PCR showed viral load of 24700 IU/ml, 16549 copies/ml.

Patient was thus diagnosed as CMV enterocolitis and started on Oral Valganciclovir. Patient's symptoms improved was hence discharged. The patient was started on extensively hydrolysed formula milk however symptoms continued to persist. Thus it was changed to amino acid formula which was tolerated well and visible weight gain was noted.

DISCUSSION

Post-natal CMV enterocolitis was first described in 1996 by Huang et al, in a 42 day old term, formula fed female who presented with three days of fever and diarrhoea, and subsequently developed ileal perforation. Since then, a steadily increasing number of cases of CMV colitis have been reported. CMV shedding in breast milk has been well documented among seropositive mothers, with maternal shedding estimates ranging from 37%–96%, and asymptomatic infant transmission occurring in up to 58% of cases.

However, in contrast to breast-milk CMV exposed preterm infants, in whom subsequent infection can manifest as a variety of illnesses ranging from acute enterocolitis to sepsis like syndrome, invasive CMV colitis has not been previously associated with breast milk transmission in term, immunocompetent infants. Other potential modes of infection include exposure at the time of delivery through viral shedding within the birth canal, as well as asymptomatic congenital infection, and post-natal horizontal transmission.

Finally, as horizontal CMV transmission, including toddler to toddler transmission, remains a leading mode of infection among young children, potential infection from childcare or other household contacts should also be considered.

Given the relative infrequency of postnatal CMV colitis despite a high reported rate of asymptomatic post-natal CMV infection among term infants, with incidence being higher amongst males, it could potentially be suggestive of subtle differences among host immune defences (X-linked or otherwise) against CMV.

Recently, components of the innate immune system including toll-like receptor-2 and 4 (TLR-2, 4), and nucleotide-binding oligomerization domain-containing protein 2 (NOD2) have been demonstrated to regulate host innate responses to CMV, and it is possible that among susceptible individuals, variations in these or other similar protein encoding genes may increase the risk of invasive CMV infection.

While no immune deficiencies were identified in our case, it is likely that such subtle immune defects may have *played a role in the illness, and that similar presentations likely warrant further genomic investigation.*

The most common colonoscopic features of CMV colitis are multiple ulcers with persistent inflammation and fibrotic changes followed by large and deep ulcers in the colon resulting in lumen stricture

CMV colitis, although rare in immunocompetent patients but it should be considered when the patients have severe diarrhoea or bloody stool. Colonoscopy or endoscopy should be done with taken multiple biopsies for finding infection in the tissue.

Our infant with chronic bloody diarrhoea was diagnosed as CMV colitis and treated with Valganciclovir, thus her symptoms resolved without any complications.

REFERENCES

1. Sue PK, Salazar-Austin NM, McDonald OG, Rishi A, Cornish TC, Arav-Boger R. Cytomegalovirus Enterocolitis in Immunocompetent Young Children: A Report of Two Cases and Review of the Literature. *Pediatr Infect Dis J*. 2016 May;35(5):573-6. doi: 10.1097/INF PMID: 26862673; PMCID: PMC4829454.
2. Manzade, F., Sayyari, A., Tajik, P. Cytomegalovirus Colitis in an Immunocompetent Patient: Report of a Case. *Journal of Pediatric Perspectives*, 2015; 3(2.1): 85-88. doi: 10.22038/ijp.2015.3982
3. Rafailidis PI, et al. Severe cytomegalovirus infection in apparently immunocompetent patients: a systematic review. *Virol J*. 2008;5:47. doi: 10.1186/1743-422X-5-47. [\[DOI\]](#) [\[PMC free article\]](#) [\[PubMed\]](#) [\[Google Scholar\]](#)
4. Klauber E1, Briski LE, Khatib R. Cytomegalovirus colitis in the immunocompetent host: an overview. *Scand J Infect Dis*. 1998;30(6):559-64.
5. Galiatsatos P1, Shrier I, Lamoureux E, Szilagyi A. Meta-analysis of outcome of cytomegalovirus colitis in immunocompetent hosts. *Dig Dis Sci*. 2005 Apr;50(4):609-16.

Who is She ??...

"She was a sweet daughter
She was a healing doctor
But then why they did her slaughter?
But then why they did her slaughter?
Everyone knows this answer
Because she was a justice fighter
She was a justice fighter ,
Now she is spread out in all of us
And they can never stop her !
And they can never stop her !!

She never thought it would be her last duty night
Because she was doing her duty right !
She deserved the safety, safety was her right,
Who cares her, when there is no light ?
Let us Stand through this protest tight,
Let us stand through this protest tight !
Untill the justice is delivered right !
Or you may be the one who might
die brutally on another duty night !!

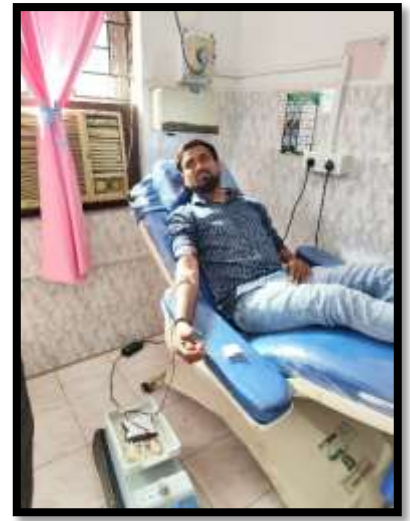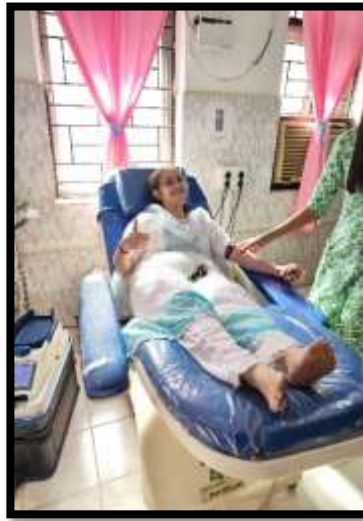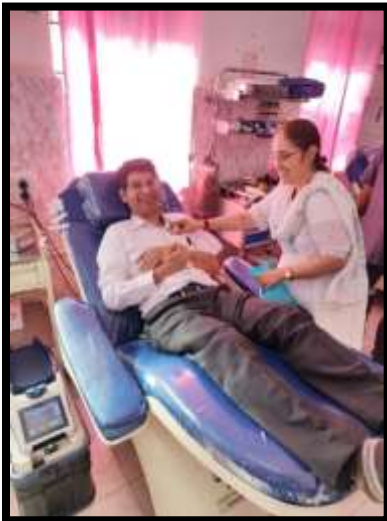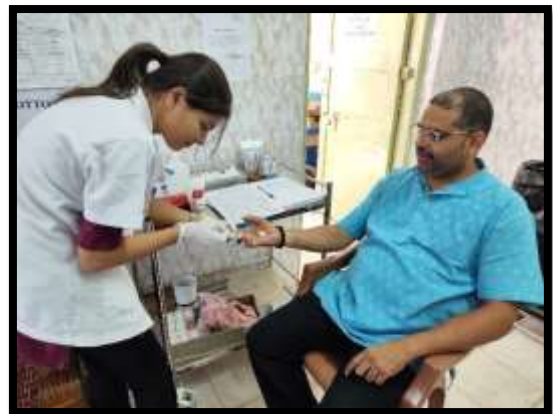We don't miss her much by name,
But definitely more by her fighting flame !
Rapists unpunished still remained same,
But lets fight to change the game
And together uplift the justice flame!
She is not only a rape victim,
But she is our justice anthem ,
She is our justice anthem !
She is our justice anthem !! "

- Dr. Chandan K. N.

Pediatric Dept. G.M.C.

(A poetic protest against tragic event at RQKar)

Greetings from IAP Goa chapter
Activities in Month of January



- On occasion of National Blood donation and organ donation we held a Team IAP Goa Chapter organized blood donation camp at Goa Mecial Coolege Blood Bank. The resonse was good. We found 1 st time donorsand regular donor, who felt great about donating the blood and were motivated to do so in future.
- We also had a mini talk on Organ donation explaining to them how to be a organ donor and what are the reasons we encourage people to come forward for same in case they are convinced.
- On National Girl Day, a short video was done by Dr. Siddhi Nevrekar that has be put on Insta Page of IAP Goa Chapter.

Link: https://www.instagram.com/share/reel_sagywpXK

Can check on Instagram/facebook account iapgoachapter



- On the occasion of World Girl Child day IAP Goa Chapter in association with IMA Ponda and Adolescent Health Cell a talk was held at by Dr. Purnima Usgaonkar at Balika Kalyanashram on 24th Jan 2025.
- A short video was done on Adolescence Nutrition and health care Dr. Siddhi Nevrekar in association with Mustifund High School, Cujira Goa. You can find the same on iapgoachapter Facebook
- Dr. Sushma Kirtani Started with Adolescence education series from episode 1 on youtube.com link being

https://youtu.be/DEaKs45XR_w?si=qRbTBTNMLr7DiHd0

- Dr. Swapnil Usgaonkar gave a talk on Use of 3% NaCl in daily practice. There was a good responses from the delegates and there was an interactive session during Question – Answer. It was held at Hotel Fidalgo on 22nd January 2025



ACTIVITIES FOR MONTH OF FEBRUARY 2025

We started with the Installation Ceremony and CME . The speakers being Dr. Bhushan Chavan and Dr. Narojhan Meshwa. Dr. Laxmi N. N. Gaunekar was the Chief Guest.

After the formal inauguration of the day. Dr. Laxmi was given a gift as a token of respect, followed by honouring the EB Member and Out Going Office Bearers Dr. Harshad Kamat (President), Dr. Priyanka Kamat Dhakankar (Secretary) and Dr. Siya Prabhudessai(Treasurer) at the hands of Dr. Gaunekar. The speaker honoured and wish the New Team with a memento which included Dr. Swapnil Usgaonker (President)/Dr. Virendra Gaonker (Vice President)/Dr. Siddhi Nevrekar (Secretary) and Dr. Akash Gaonkar (Treasurer). Incoming President gave a brief talk on what his vision is for this tenure.



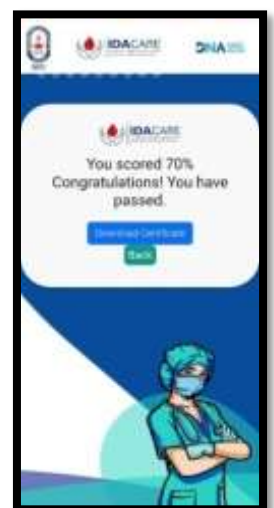
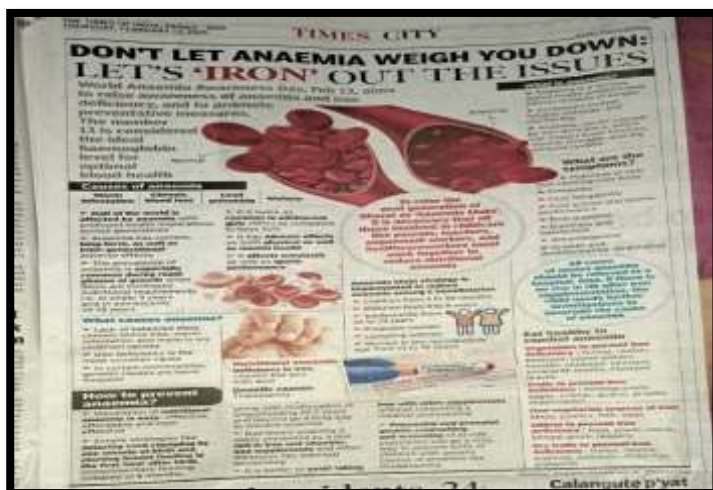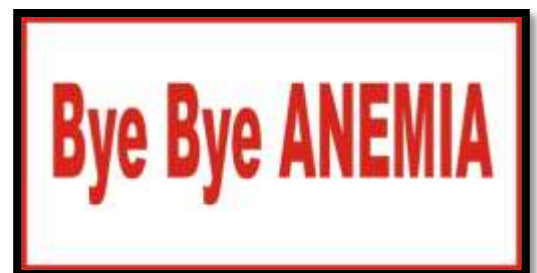2. All members in their respective Clinic created awareness about the meaning of anaemia, its repercussion and adherence to the medicines .Also there was discussion about when to give an when to stop.



3. Dr. Sushma Wrote an article on Anaemia to create awareness and ways to prevent it



4. Anaemia workshop was held for Healthcareworkers with a pretest and post test



5. “Raise Your Hands for Blood Health” 13th February 2025



5. A glimpse of all the office bearers work towards Anaemia free Goa



6. Asilo Hospital (North District Hospital) conducted Anaemia diagnosis and awareness about the same

Video link:

https://youtu.be/xSt11zGn43E?si=pO9di5KM_AnOMjR-



7. Anaemia detection Camp was held in Association with IMA Ponda Branch



8. Talk given by Dr. Siddhi Nevrekar about Deworming and its association with Anaemia on Akashwani – FM Rainbow

<https://mail.google.com/mail/u/0?ui=2&ik=41df5c1056&attid=0.1&permmsgid=msg-a:r-1677037037553516673&th=195761689cb7e966&view=att&disp=safe&realattid=19576164489d9509ed71&zw>



9. <https://www.instagram.com/reel/DGnyI4oqxsq/?igsh=enBmYmlhOTkzbWpp>

<https://youtu.be/YXnlCd9qbNU?si=DuyT1PY0qI17s09L>

10. Talk by Dr. Swapnil Usgoankar on Prudent media on Anaemia

11. <https://youtu.be/Lm7Nwu52Fm8?si=LlmQvhOrRC2MBv75>

Talk by Dr. Akash Gaonkar on Anaemia, causes, prevention and diet

12. Dr Sushma Kirtani conducted under Anaemia Mukta Bharat; a hemoglobin detection camp was conducted at my clinic on 12th April 2025. Parents, grandparents, caretakers, kids and staff working in nearby chemists who wanted to check their hemoglobin attended. 18 adults and 7 children were tested. Many young girls from 20 to 23 yrs had HB ranging from 6 gms % to 11gms%. Young males between 25 to 35 yrs had HB in the range of 12.3 to 12.5 gms %. Kids had Hb from 8.5 to 10.2 (2 to 8 yrs). This shows anaemia is high in random sample of population tested during the camp. Diet, nutrition advice and foods rich in iron were explained. Young adults were asked to see their physicians and do complete blood checkup to rule out causes of anaemia and its proper management.

13. Dr. Kritika Wagle gave a talk on Micronutrient and Antioxidants



Activities for Month of March

1. World obesity Day
2. Dr. Swapnil Usgaonker spoke on Child hood obesity on prudent media

<https://www.instagram.com/reel/DGnyI4oqxsq/?igsh=enBmYmlhOTkzbWpp>

3. Dr. Abhijit Shanbag spoke about Obesity in his clinic (video can be viewed on iapgoachapter FB page)



4. Dr. Siddhi Nevrekar spoke to the health care worker and created awareness regarding MALNUTRITION
5. Laid more focus on Obesity...how to know whether you child , Malnourished i.e either under weight or overweigh shared growth charts n also the BMI value so that they realise whether in which direction they believe. The right one for their child... The complications and health issues were . Discussed and how to start and maintain Healthy Balanced Diet.
6. Dr. Punam Shambhaji gave a talk on obesity on Doordarshan –
<https://youtu.be/baKTlwP4VD4?si=ew0UhLijUR0BpCCD>
7. Dr. Kritika Wagle, gave a talk on FM rainbow regarding What is Obesity, how to occur, the diseases associated life threatening issues the child can face, management with lifestyle modifications



8. Dr. Swapnil gave a Talk at Edward's Yard on Respiratory diseases



8. Dr Swapnil Usgaonker, Dr Siddhi and Dr Akash took the initiative to celebrate 'International Womens Day' on 9th March. Such an unique was done for the first time such a programme was conducted by IAP Goa Chapter under the guidance of Dr. Sushma Kirtani.

We had a CME by 2 of our known and respected doctors based on HPV protection, early diagnosis and treatment by Dr Vishal Gude, Senior Gynaecologist and our very own Dr. Harshad Kamat - ex president spoke on cervical cancer detection and screening and HPV vaccine respectively.

5 Eminent senior Lady Pediatricians who were felicitated on this occasion

- Dr Laxmi N.N Gaunekar
- Dr Philomina De Sousa
- Dr Lily Sequeira and
- Dr Purnima Usgaonker
- Dr Mimi Silveira,

For the first time the concept of IAP Goa Diva was implemented, we had 3 Charming and beautiful young Divas with Dr. Maneka Fernandes winning the first place and golden crown Dr. Aparna Wadkar first runner up with Dr. Kalpana as 2nd runner up.

It was full of fun and each member showed involvement by IAP Goa members who attended the CME. The CME was attended by 48 members

A short glimpse of the Women Day activities



9. On 16th March 2025, we organized “**Asthma Training Module**” in association with IAPNRC. The faculty for same was Dr. Shirshir Modak, Dr. Sushant Mane and Dr. Anushula Tayal. It was very crisp and to the point sessions, answering queries that we come across in our OPD and at IPD level to. The faculty had a very apt and an answer to each question with reasoning. There were 49 attendees



10. World Oral Health Day is observed on 20th Marchas a part of this we have kept a " Salad dressing competition " on 19/03/25 at 12.00pm which will tickle our taste buds as well as our grey cells.

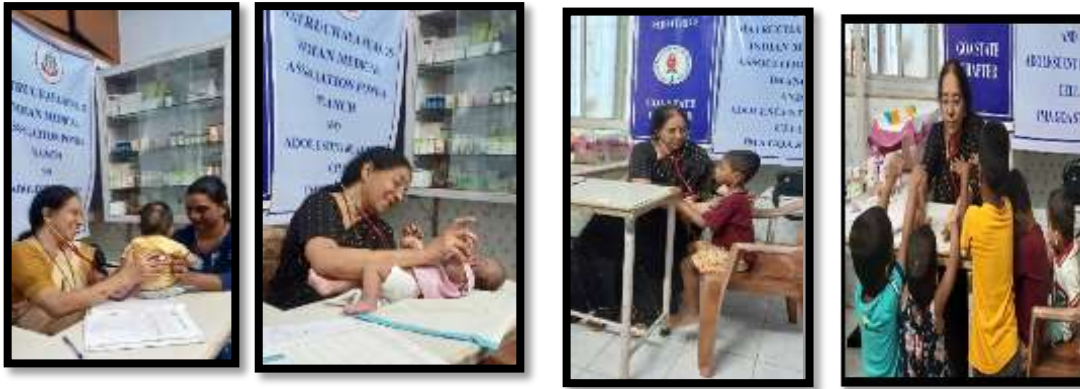World Oral Health Day March 20th

SDH Ponda conducted a salad competition for the staff of SDH

“Happy mouth happy mind”



11. Weekly Matruchaya Health camps are conducted by Dr. Purnima Usgaonker



12. Pediatric Neuro Rehab Center(PNRC) Goa Medical College and Hospital celebrated world Down Syndrome Day 2025 on 21st of March . The theme for this year's program was "Improve our support system" and the program was planned keeping that in mind.

The program was attended by children with Down Syndrome who are receiving therapy in PNRC. A few children from Fairyland school who were previously receiving therapy in PNRC and are currently going to school were in attendance to the program along with their teacher.

PNRC had organised/ conducted 2 competitions , one was a poster competition for students of MBBS,BPT and BOT .The theme for this was " Improve our support system" which was in accordance with this year's theme of world Down Syndrome Day.

We received an overwhelming response for the same. Dr Shilpa Joglekar,Department of pediatrics and Dr Shubhangi Borker Department of Microbiology , were our esteemed judges for the competition.

The second competition ' the healthy plate ' was organised for the mother's of children with Down Syndrome, where they had to prepare healthy and nutritious dishes that are children friendly without compromising on the taste. This competition too had a great response from parents and was a huge success.

Ward sister Rajeshree and Ward sister Kajal were the judges for this competition. The Downs Syndrome Day was organised in collaboration with Novi Suruvat (NGO). Dr Philomina Dsouza and Novi Suruvat have been very generous with their time, support and resources, without which this day would not have been possible.

The other activities included hand and face painting for children and a few games for children along with their parents. Children and parents won a lot of prizes for the games and enjoyed the evening. The IMA student wing joined hands with PNRC to conduct this program smoothly as their volunteers enthusiastically provided assistance to our children with Down Syndrome to participate in the various activities by being their 'support system' .

An audio visual presentation done by the parents to highlight the journey of their child was the highlight of the program. We all got to experience and understand the importance of various support systems that the children and parents need in this journey.

The support of the family at first, the sensitivity of the pediatrician to gently give them the diagnosis and hope and the various therapists who then hand hold these children along with their family to achieve various milestones from walking and talking to making them independent participants of society.

Each therapist contributing a different life skill that is essential for them to be independent in their activities of daily living. The school and teachers are an integral part of this journey as they impart education and training and bring out the best in each child by highlighting and honing their strengths.

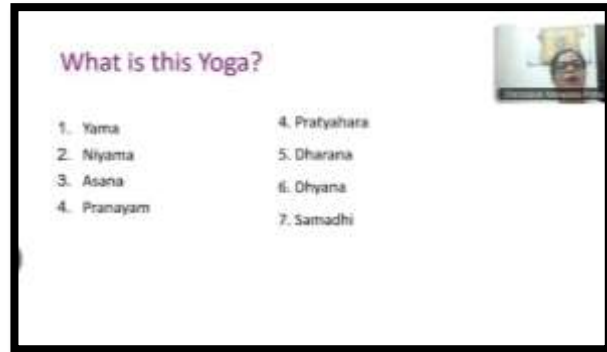
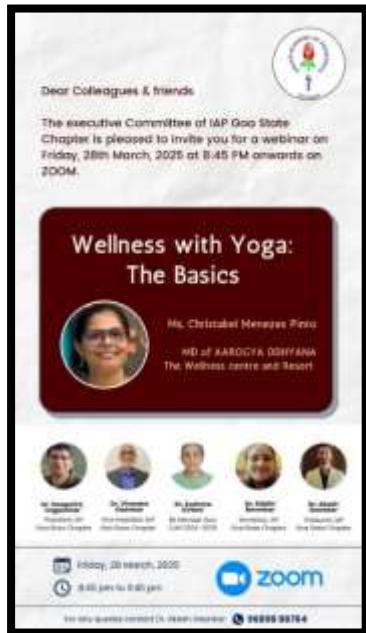The journey that begins at birth with a tiny infant and scared parents goes on to become an inspiring tale for fellow children with Down Syndrome and society at large. The whole team of PNRC was involved in planning for the Day . All the therapists and staff planned each activity meticulously to make this event a success. No event is possible without the support guidance and encouragement of the Head of Department of Pediatrics, Dr Vaishali Joshi and The Dean, Dr S. M Bandekar of Goa Medical College.



13. On the 28th March we had a webinar on Yoga and wellness. There were 22 participants

Link for webinar on Yoga

https://us06web.zoom.us/rec/share/D_dK_1NhgF3OTx5JN0YG5_ikqUamFRE4_ypHJWWPWWC8hliuS5hm7UQg-luhAIjm.ytx2nP8l3AniHP8K



14. Part of the camp organised at Balikakalyan Ashram Talauli by IMA Ponda, IAP Goa Branch, Adolescent Health Cell of IMA Goa State, and Matruchaya Seva on 29/3/25 3.30pm. to 5.00pm. Dr. Amritha Shenoy and Dr. Akshata Baliga, the consultant Dermatologists from Ponda, examined 35 girls and advised them towards medical treatment and the preventive measures towards the same.



15. On Occasion of 'World Hemophilia day'

The Department of General Medicine and Pediatrics (on behalf of IAP) in collaboration with Medical Education Cell and Academic section GoaMedical College, organized a“Haemophilia Awareness program and CME on Centre experience fromGoa Medical college and AIIMS Delhi in the management of Hemophilia”.

The inaugural function was graced by the honourable health minister Shri Vishwajit Rane who extended hole-hearted support for the people with Hemophilia being treated at Goa Medical college.

- Dr. Ramnath Nevrekar, Associate Professor in department of General Medicine and The Department of General Medicine and Pediatrics in collaboration with Medical Education Cell and Academic section Goa Medical College, organized a “Haemophilia Awareness program and CME on Centre experience from Goa Medical college and AIIMS Delhi in the management of Hemophilia”.

Goa medical college had shifted many patients from on demand therapy to prophylaxis with IV factor infusions. However being on Efficizumab prophylaxis was much more convenient with respect to the ease of Subcutaneous administration and reduced frequency of therapy from twice a week to once in 2 weeks, thereby ensuring adherence to therapy.

The guest speaker for the CME, Dr. Tulika Seth, Professor Hematology, AIIMS, New Delhi spoke on her experience with Efficizumab in her institute and highlighted its cost. Dr. Monika Puri, from Roche pharmaceuticals spoke at the occasion and extended her support to Hemophilia care in Goa.

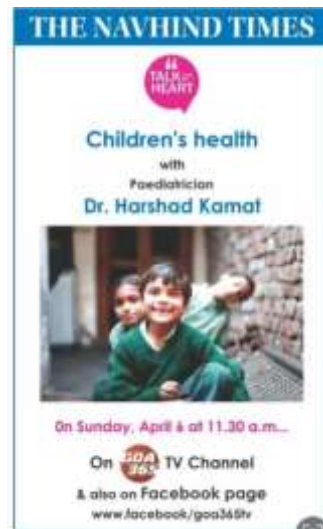
- Dr. Lorraine D'Sa, Assistant Professor in department of Pediatrics (Member IAP Goa) spoke on addressed the it and pediatric patients” respectively.

They emphasized that this new molecule Some patients who were developing recurrent bleeds and target joints got complete joint mobility after being started on this molecule.

Goa medical college had shifted many patients from on demand therapy to prophylaxis with IV factor infusions. However, being on Efficizumab prophylaxis was much more convenient with respect to the ease of Subcutaneous administration and reduced frequency of therapy from twice a week to once in 2 weeks, thereby ensuring adherence to therapy.



16. Vaccination Day was celebrated by making patients aware about the optional vaccine which are no longer optional. A short talk and counselling done by IAP members in their OPDs



1. Dr. Harshad Kamat spoke on Immunization and its necessity on GOA 365
2. Dr. Siddhi Nevrekar spoke on Vaccination – Basics and newer vaccines that have come and should be given when and why on Prudent media
3. Article written by Dr. Akash Gaonkar-

17Dr Ira's Write up on the newspaper



❖ Kindly note...for more activities and details please visit FB page iap goachapter and also on Instagram and facebook.

Thank You...